

Spontaneous endometriosis in cynomolgus monkeys as a clinically relevant experimental model

A. Nishimoto-Kakiuchi¹, S. Netsu², S. Okabayashi³, K. Taniguchi¹,
H. Tanimura¹, A. Kato¹, M. Suzuki¹, T. Sankai^{3,*}, and R. Konno^{2,*}

¹Research Division, Chugai Pharmaceutical Co., Ltd., 200 Kajiwara, Kamakura, Kanagawa 247-8530, Japan ²Department of Obstetrics and Gynecology, Jichi Medical University Saitama Medical Center, 1-847 Amanumacho, Omiya-ku, Saitama, Saitama 330-8503, Japan ³Tsukuba Primate Research Center, National Institutes of Biomedical Innovation, Health and Nutrition, 1-1 Hachimandai, Tsukuba, Ibaraki 305-0843, Japan

*Correspondence address. Tsukuba Primate Research Center, National Institutes of Biomedical Innovation, Health and Nutrition, 1-1 Hachimandai, Tsukuba, Ibaraki 305-0843, Japan. E-mail: t-sankai@nibiohn.go.jp (T.S.)/Department of Obstetrics and Gynecology, Jichi Medical University Saitama Medical Center, 1-847 Amanumacho, Omiya-ku, Saitama, Saitama 330-8503, Japan. E-mail: kryo772007@yahoo.co.jp (R.K.)

Submitted on December 20, 2017; resubmitted on March 1, 2018; accepted on April 4, 2018

STUDY QUESTION: Does spontaneous endometriosis in cynomolgus monkeys have the characteristics required of a good experimental model?

SUMMARY ANSWER: Spontaneous endometriosis in cynomolgus monkeys exhibited similar clinicopathological characteristics to the human disease and was useful as an experimental model.

WHAT IS KNOWN ALREADY: The prevalence of endometriosis in autopsied cynomolgus monkeys (*Macaca fascicularis*) in a breeding colony was reported to be 28.7% in 1993. The histopathological findings we reported recently showed that components of spontaneous endometriosis were not only endometriotic epithelium and stromal cells (CD10-positive) with hemorrhage and inflammation, but also smooth muscle metaplasia and nerve fibers.

STUDY DESIGN, SIZE, DURATION: During routine medical examinations at a research facility from 2008 to 2012, 614 female cynomolgus monkeys of reproductive age (6–25 years) were screened for endometriosis by the presence of regular menstrual bleeding, serum CA125 levels and palpation of the abdomen. In total, 29 monkeys were selected as subjects for the following study.

PARTICIPANTS/MATERIALS, SETTING, METHODS: Of the 29 monkeys selected, 15 were diagnosed with endometriosis by laparoscopy and/or open surgery. The monkeys were monitored by observing their general condition, and eight of these were monitored using laparoscopy and MRI. In addition, to investigate appropriate screening parameters and endometriosis-associated biological parameters in monkeys, we retrospectively examined general laboratory parameters that correlate to the menstrual cycle and disease status.

MAIN RESULTS AND THE ROLE OF CHANCE: The combination of CA125 serum levels (this was a useful marker for chocolate cysts), palpation of the abdomen, and fecal abnormalities was the most efficient screening method for diagnosing monkeys with endometriosis. Each animal could be diagnosed and assigned a disease stage by laparoscopy. While monitoring the disease stage by laparoscopy and/or MRI, disease status in individual monkeys was mainly stable or was progressive for 2–7 months. The detection rate by screening was low (15/614) but age-specific analysis suggests that screening would be more efficient if a colony for an endometriosis model is maintained with 11–20-year olds. As an endometriosis-associated biological parameter, the decrease in food consumption that coincided with menstruation was selected and correlated well (R^2 value = 0.8239) with disease status (according to a modified adhesion revised American Fertility Society score).

LARGE SCALE DATA: N/A.

LIMITATIONS, REASONS FOR CAUTION: Peritoneal fluid was not analyzed because a smaller amount is produced in cynomolgus monkeys than in baboons. Although clinical endometriosis-associated pain is evaluated in women using a visual analog scale, pain could not be directly evaluated in this non-human primate model.

WIDER IMPLICATIONS OF THE FINDINGS: Although cynomolgus monkeys are relatively small (2–5 kg) primates, laparoscopy and MRI make it possible to evaluate spontaneous endometriosis in these monkeys and to monitor its development over time. Spontaneous endometriosis in cynomolgus monkeys is a useful model for evaluating disease progress and drug efficacy because they have similar lesions to those in humans, and conventional laboratory methods and parameters for assessment are well established.

STUDY FUNDING/COMPETING INTEREST(S): No external funds were used for this study. A.N.-K., K.T., H.T., A.K. and M.S. are full-time employees of Chugai Pharmaceutical Co., Ltd. R.K. received a consultancy fee from Chugai Pharmaceutical Co., Ltd. and lecture fees from Chugai Pharmaceuticals, Japan Vaccine Co. Ltd., Merck & Co., Mochida Co. Ltd., Roche Diagnostics, and BD, unrelated to the submitted work. S.N., S.O. and T.S. have nothing to declare.

Key words: spontaneous endometriosis model / screening / MRI / laparoscopy / food consumption / time-course monitoring / cynomolgus monkey

Introduction

The clinical manifestations of endometriosis are dependent not only on estrogen but also on inflammatory agents, but a full understanding of its etiology remains elusive. The main symptoms in humans are severe dysmenorrhea, chronic pelvic pain, bowel symptoms and infertility (Greene et al., 2009), and since current therapies are not adequate to manage the disease in the long term, an endometriosis model that reflects clinical disease status is needed to clarify its etiology and to develop new drugs.

Spontaneous endometriosis in non-human primates (NHPs) is considered useful for researching the disease because the anatomy of NHP reproductive organs is similar to that of humans (Story and Kennedy, 2004; Braundmeier and Fazleabas, 2009; Yamanaka et al., 2012). Although the menstrual cycle of rhesus monkeys (*Macaca mulatta*) is seasonal, that of baboons (*Papio*) and cynomolgus monkeys (*Macaca fascicularis*) is similar to the human menstrual cycle (~4 weeks), so spontaneous endometriosis reported in cynomolgus monkeys (Fantom and Hubbard, 1983; Ami et al., 1993) and baboons (Merrill, 1968; D'Hooghe et al., 1991) is considered relevant. The histological characteristics have also been described fully and are considered to be clinically relevant in baboons (D'Hooghe et al., 2009) and cynomolgus monkeys (Nishimoto-Kakiuchi et al., 2016). Baboons are reportedly useful for endometriosis research because they are larger than cynomolgus monkeys, which makes it easier to observe the disease by laparoscopy and to obtain tissue samples. Conversely, being smaller in body size and a common laboratory animal, cynomolgus monkeys are easier to control in the laboratory setting (Nishimoto-Kakiuchi et al., 2016; Yamanaka et al., 2012).

There are at least three requirements for a spontaneous endometriosis animal model to evaluate drug efficacy: screening, diagnosis with staging and monitoring. Although D'Hooghe et al. (1992) reported diagnosis and monitoring with staging over 30 months in baboons by laparoscopy (D'Hooghe et al., 1996a; 1996b), a systematic approach to screening for spontaneous endometriosis in NHPs from a general population has not been reported. In addition, although MRI monitoring has recently received much attention as a non-invasive method in the clinical setting (Bazot et al., 2004; Takahashi et al., 2016), there is no report of its use in baboons or cynomolgus monkeys. Because of

this lack of a model with the appropriate requirements, we tried to establish methods for screening, staging and monitoring of spontaneous endometriosis in cynomolgus monkeys for the first time.

Another important parameter for an endometriotic model is pain, which is the main symptom and main endpoint in clinical endometriosis research in humans (Dunselman et al., 2014). Because pain cannot be evaluated directly in animal models, if a parameter(s) that correlates with endometriosis can be established, it would be valuable when applied to an endometriosis animal model. For this purpose, the current study investigated parameters that may correlate with the menstrual cycle and endometrial status, and finally compared the characteristics that make cynomolgus monkey and baboon models appropriate for evaluating the efficacy of therapies.

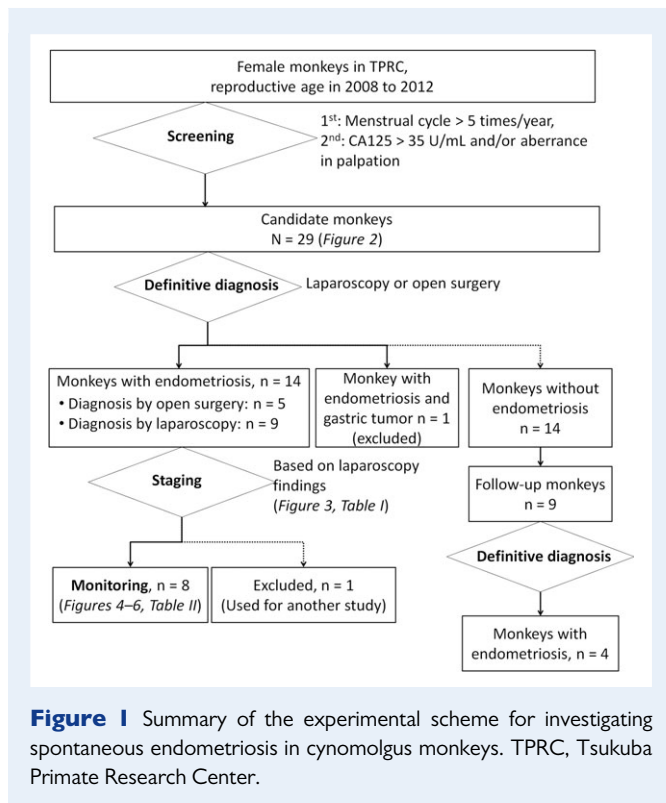
Materials and Methods

Ethical approval

The study was conducted on cynomolgus monkeys in the breeding colony of Tsukuba Primate Research Center (TPRC) at the National Institute of Biomedical Innovation, Health and Nutrition, Ibaraki, Japan. All monkeys that were used in this study were cared for according to procedures approved by the Animal Care and Use Committee of the National Institute of Biomedical Innovation, Health and Nutrition, which reviews study plans according to the guidelines in Japan set out in the 'Ministry of Health, Labor and Welfare: Basic Policies for the Conduct of Animal Experimentation'. Besides, protocols for all experiments involving animals were in compliance with the guidelines set by the same institute for the care, use and biological hazard countermeasures of laboratory animals.

Animals

The TPRC was established in Tsukuba in 1978. Cynomolgus monkeys were originally brought from the Philippines, Indonesia, and Malaysia and, although colonies were sometimes crossbred, the monkeys were basically bred within a colony of animals from the same geographic origin. The monkeys which were observed for diagnosis were first to third generation descendants from the imported monkeys. This study was conducted using 614 female cynomolgus monkeys of reproductive age (6–25 years old) in the breeding colony of TPRC from 2008 to 2012. The environment of the animal room was set at $25 \pm 2^\circ\text{C}$ room temperature, $60 \pm 5\%$ relative



humidity, and a 12 h light-and-dark cycle. The animals were given water *ad libitum* and fed daily with 70 g commercially available solid food (35 pieces of type AS; Oriental Yeast Co., Ltd., Tokyo, Japan) and 100 g apples.

During the screening phase (explained below), out of 29 monkeys that were selected as possible candidates, 15 were diagnosed with endometriosis by laparoscopy and/or open surgery. Of these, the nine animals that were diagnosed by laparoscopy were categorized according to their disease stage, and eight of them were subjected to monitoring for 2–7 months (Fig. 1).

Another five healthy female monkeys were selected arbitrarily, and their food consumption was observed for 8 weeks as a control.

Screening

We selected 29 candidate monkeys (7–21 years old) by screening primarily for regular menstrual bleeding (five times per year or more) and secondarily for high values of serum CA125 (>35 U/mL) and/or aberrance found on palpation during routine medical examination. Serum CA125 concentration was measured with HISCL CA125 reagent (Sysmex Co., Ltd., Kobe, Japan) and an automated hematology analyzer (K-4500; Sysmex Co., Ltd., Kobe, Japan). Palpation of the abdomen was performed by veterinarians with the monkeys supine and under anesthesia with 5 mg/kg ketamine hydrochloride (Ketalar; Daiichi Sankyo Propharma Co., Ltd., Tokyo, Japan) and 1 mg/kg xylazine hydrochloride (Celactal; Bayer AG, Leverkusen, Germany). Typical aberrances found by palpation are enlargement, induration, irregular shape of the uterus and abdominal distension.

At TPRC, the general condition of all monkeys is observed daily and recorded as follows: feces (normal, loose, diarrhea, no feces); amount of menstrual bleeding (no bleeding, spotting, mild bleeding, heavy bleeding); food consumption (most, half, little); and locomotor activity (normal, low activity, inactivity/lying down). In a health examination every 2 years, blood

is analyzed by measuring hematological indices and other biochemical tests including measuring C-reactive protein using an automated hematology analyzer (K-4500; Sysmex Co., Ltd., Kobe, Japan). Finally, clinicopathological status is also recorded by noting mating times, pregnancy, delivery, cesarean sections and abortion.

To increase the number of endometriotic monkeys obtained, we increased the screening parameters by retrospectively assessing the routine laboratory parameters recorded at TPRC. These additional screening parameters, and combinations of all the screening parameters, were then evaluated according to their positive predictive value (PPV) or 'sensitivity.' The PPV and sensitivity were defined as: $PPV = \text{true positive} / (\text{true positive} + \text{false positive})$; $Sensitivity = \text{true positive} / (\text{true positive} + \text{false negative})$.

In addition, serum CA125 levels were compared between the endometriotic animals with or without chocolate cyst(s).

Diagnosis with staging

Fifteen out of the 29 monkeys were definitively diagnosed with endometriosis by open surgery, from which we could be sure of obtaining a biopsy sample for pathological analysis ($n = 5$), or by laparoscopy ($n = 10$, of which one monkey was excluded from the rest of the study because of a gastric tumor). Biopsy samples were taken from all five monkeys diagnosed by open surgery and, as our laparoscopic skills improved, from three of the monkeys diagnosed by laparoscopy. The samples were fixed with 4% (V/V) neutral-buffered formalin and stained with hematoxylin and eosin. The nine monkeys diagnosed by laparoscopy were evaluated for their disease status based on lesion size, location, and adhesions. However, we decided not to compare the staging data from open surgery with those from laparoscopy because data on smaller lesions, which are harder to detect in open surgery, would be inconsistent. Observations by open surgery and laparoscopy were both performed under anesthesia with 5 mg/kg ketamine hydrochloride (Ketalar; Daiichi Sankyo Propharma Co., Ltd., Tokyo, Japan) and 1 mg/kg xylazine hydrochloride (Celactal; Bayer AG, Leverkusen, Germany) followed by isoflurane (Isoflurane Inhalation Solution; Pfizer Inc., NY, USA).

To adjust the scoring method in cynomolgus monkeys, the revised American Fertility Society (r-AFS) score (1985) was modified in the following two ways (modified r-AFS score): the size criteria were changed to 5 and 15 mm; and an item was added for adhesions at the vesicouterine pouch (complete, partial, open). The monkeys underwent laparoscopy twice during the monitoring period, and we used the modified r-AFS score to evaluate lesion size, location and adhesion.

Monitoring

Disease monitoring is the final step in the experimental scheme shown in Fig. 1, and it was used to assess the usefulness of the animal model for evaluating drug efficacy. One of the nine monkeys that were diagnosed by laparoscopy was excluded from the present study and used in another study. The disease status of the eight monkeys in which endometriosis had been diagnosed was monitored by laparoscopy and MRI (Siemens Healthcare Japan, Inc., Tokyo, Japan) for 2–7 months. The monitoring schedule of each animal is shown in Supplementary Fig. S1. T1-weighted images were taken to evaluate the cysts quantitatively. Since periodic analysis showed that cyst volume was stable in any estrus period (menstrual period, proliferative period and secreted period), we considered that the data of all time-points were comparable.

In time-course monitoring, we evaluated the lesions quantitatively after comparing the detectable lesion profile (size and location) taken by MRI with the laparoscopic findings.

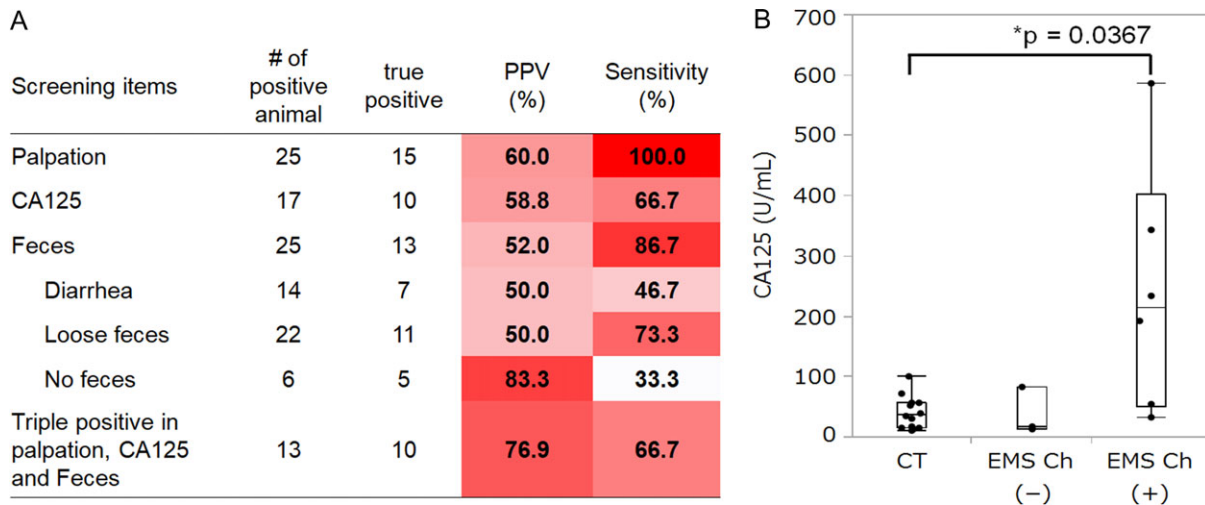


Figure 2 Retrospective assessment of items used for screening cynomolgus monkeys with endometriosis. **(A)** Heat map of the positive predictive value (PPV) and sensitivity for endometriosis of each screening item. **(B)** Relationship between CA125 and presence of chocolate cysts. Serum CA125 was significantly higher in endometriosis monkeys with chocolate cysts ($N = 6$) than in control non-endometriosis monkeys ($N = 14$) ($P = 0.0367$, Steel test), whereas in those without chocolate cysts ($N = 3$) it tended to be similar to the control monkeys. EMS, endometriosis.

An endometriosis-associated biological parameter

Previously, we reported that a decrease in food consumption in the menstruation period was observed in monkeys with histologically confirmed endometriosis (Nishimoto-Kakiuchi et al., 2016); therefore, we selected it as a candidate endometriosis-associated biological parameter. With this aim, we measured the food consumption of eight monkeys for 12 weeks and analyzed its correlation with the modified r-AFS score at the second laparoscopy (Supplementary Fig. S1).

Statistical analysis

We analyzed the correlation between CA125 and the presence of 'chocolate' cysts using the Wilcoxon rank-sum test, and also assessed the correlation between food consumption and the modified r-AFS scores of the second laparoscopy using a correlation coefficient R^2 value (Microsoft Excel, Microsoft Co., WA, USA).

Results

Screening

Laparoscopic or open surgery examinations facilitated definitive diagnosis in 15 out of 29 candidate monkeys, that had earlier been selected by the presence of regular menstruation and then by an aberrance on palpation and/or CA125 >35 U/mL in serum. The diagnosis of endometriosis was also histologically confirmed from biopsied tissue in eight of the 15 monkeys. The definitively diagnosed monkeys ranged from 8 to 20 (median 14) years of age. Most of them were older than 11 years.

Because the PPV of the first screening method (using elevated CA125 and/or palpation) was 51.7% (15/29), we retrospectively analyzed the general screening items in order to find a method with a higher PPV as a more effective screening for endometriosis and with higher

sensitivity to avoid oversights (Fig. 2A). Palpation is a good first screening step because its sensitivity was 100.0% (15/15), and thus aberrances could not be missed. We also found that the observation of feces was a good item for screening; especially, the PPV of no feces was high (83.3%; 5/6), and the triple combination of aberrances on palpation, high CA125 levels and fecal abnormalities further increased the PPV to 76.9% (10/13). Although the sensitivity of no feces was low (33.3%; 5/15), the sensitivity of fecal monitoring overall was high (86.7%; 13/15), followed by that of the triple-positive combination (66.7%; 10/15). In the course of the current study, we found serum CA125 levels to be another clinicopathological feature of monkeys with endometriosis. Levels tended to be high in monkeys with chocolate cyst and low in those without chocolate cyst (Fig. 2B).

As part of this study, we followed up the nine monkeys that had been found not to have endometriosis in the first examination and continued to screen them to see whether endometriosis would develop (Fig. 1). In this follow-up phase, endometriosis was found in four of the nine monkeys. This indicates that, even if they have been diagnosed as negative, there is a high possibility that endometriosis will occur in monkeys with high risk factors (aberrant palpation findings, fecal abnormalities and/or high CA125 levels). Intensive monitoring of animals with these factors could be an efficient way to identify monkeys with endometriosis.

Regarding the other screening items, heavy menstrual bleeding had a high PPV at 75.0% (6/8), but low sensitivity at 40.0% (6/15). C-reactive protein, locomotor activity, mating times, pregnancy, delivery and cesarean sections did not correlate with any disease aspect (data not shown).

Diagnosis with staging

Representative laparoscopic images are shown in Fig. 3. As these images show, it was possible to detect small endometriotic lesions (i.e. cystic/nodular/subtle lesions and adhesions) with full laparoscopic

observation, and to observe adhesions on the pouch of Douglas, even when the body size of the female monkeys was small (2.4–5.0 kg in this study). With skill and good laparoscopy technique, small lesions in the peritoneal wall and large chocolate cysts could be detected (Fig. 3A and B), and their color distinguished (red, pink, brown, blue,

black or white). Adhesions were observed in the ovaries, fallopian tubes, pouch of Douglas and vesicouterine pouch (Fig. 3C and D). Of note as a characteristic of endometriosis in cynomolgus monkeys, lesions and adhesions at the vesicouterine pouch were frequent (44.4%; 4/9). Taken together, this information allowed us to calculate a modified r-AFS score for each animal, and to assign a corresponding disease stage (stages I–IV) (Table I).

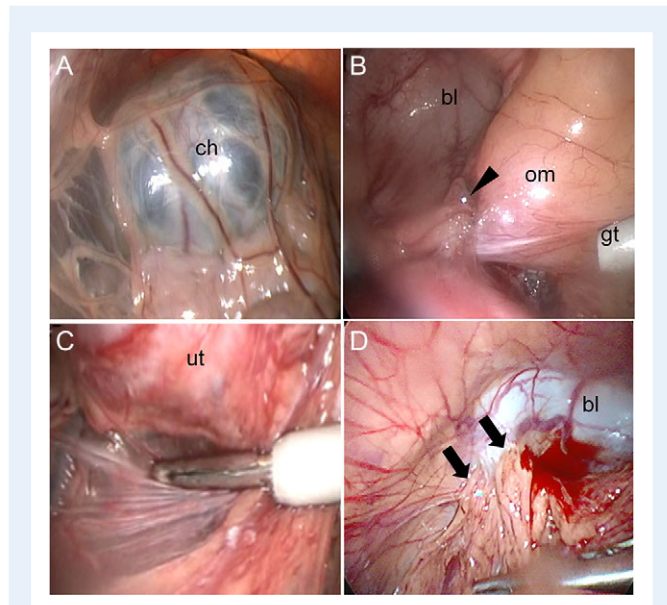


Figure 3 Representative laparoscopic images of endometriosis in cynomolgus monkeys. (A) Chocolate cyst (ch, 94203). (B) Small lesion (arrowhead) in the peritoneal cavity (92193). (C) Adhesion at the Douglas pouch (93124). (D) Adhesion (arrow) at the bladder (93124). ch, chocolate cyst; bl, bladder; om, omentum; ut, uterus; gt, guide tool.

Monitoring

Monitoring by laparoscopy and r-AFS scoring was performed at intervals (2–7 months) (Fig. 4 and Supplementary Fig. S1). Disease status tended to be maintained and sometimes progressed from the first to the second observation (Fig. 4B–D).

Large cystic lesions could be monitored using T1-weighted MRI, which allowed us to detect cystic lesions behind adhesions and deep infiltrating endometriosis, even when it was difficult to evaluate them using laparoscopy. For example, MRI clearly identified that a chocolate cyst expanded into the serosa of the dorsal uterus in monkey 89102 (Fig. 5A), but laparoscopy could only distinguish chocolate cysts in that particular monkey (Fig. 5B). The total volume of the cystic lesion in each animal tended to be stable (Fig. 5C), as was the case with the r-AFS score. These individual merits and demerits of laparoscopy and MRI are summarized in Table II so that the monitoring methods can be easily compared.

Endometriosis-associated biological parameter

As a candidate endometriosis-associated biological parameter, we measured the food consumption of eight monkeys with endometriosis in the monitoring stage and compared the results to those in healthy controls ($n = 5$). Food consumption in the healthy animals was

Table I Modified revised American Fertility Society score and stage for each of the nine cynomolgus monkeys with spontaneous endometriosis.

Animal ID	95001	94123	92193	91001	93124	89074	96146	94203	89102
Size									
Peritoneum	0	I	I	0	0	2	0	0	4
Right ovary	0	0	0	16	20	20	4	20	NE
Left ovary	0	0	0	0	0	0	20	NE	0
Size score	0	I	I	16	20	22	24	20	4
Adhesions									
Right ovary	0	0	0	2	4	16	16	16	16
Left ovary	0	0	0	0	8	1	16	16	16
Right tube	0	0	0	0	0	0	0	16	16
Left tube	0	0	0	0	0	0	0	16	16
Pouch of Douglas	4	4	4	0	4	4	0	0	40
Vesicouterine pouch	0	0	4	0	4	0	4	NE	4
Adhesion score	4	4	8	2	20	21	36	64	108
Total score	4	5	9	18	40	43	60	84	112
Disease stage	I	I	II	III	III	IV	IV	IV	IV

NE, not examined.

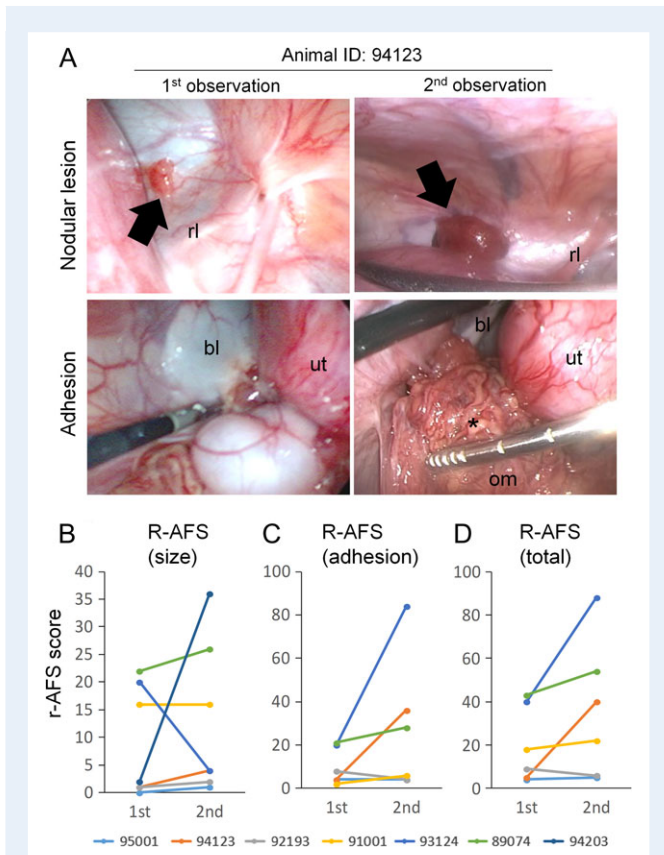


Figure 4 Time-course monitoring of endometriosis in cynomolgus monkeys by laparoscopy. **(A)** Representative images of laparoscopy during time-course monitoring, showing a nodular lesion (upper) and adhesion (lower). Lesion color changed from pink to red (arrow) and the adhesion progressed to the omentum (asterisk). **(B–D)** Disease monitoring using the revised American Fertility Society (r-AFS) score: size score **(B)**, adhesion score **(C)** and total score **(D)**. rl, round ligament.

confirmed to be 100.0% (median), whereas it decreased in the monkeys with endometriosis and often dropped even further during menstrual bleeding (Fig. 6A and B). We also found that food consumption during menstrual bleeding was correlated to the adhesion r-AFS score (Fig. 6C), but not to the size r-AFS score (data not shown).

Finally, Table III presents the characteristics of spontaneous endometriosis in cynomolgus monkey as an experimental model and compares them with those in baboon.

Discussion

There is a scientific need for an endometriosis model with which to clarify the etiology of this disease and to develop novel drugs, and spontaneous endometriosis of NHPs is a promising candidate. We considered that there are three requirements for a spontaneous endometriosis model in which drug efficacy can be evaluated: screening, diagnosis with staging and monitoring.

In order to screen cynomolgus monkeys with spontaneous endometriosis from a general population, we assessed several parameters that can be obtained as part of usual laboratory practice, and we

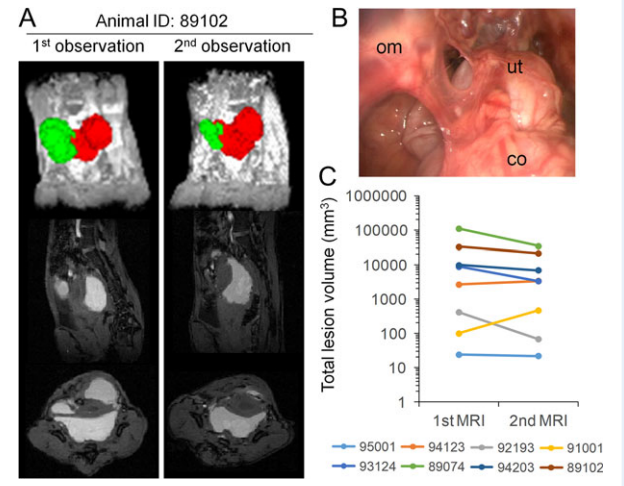


Figure 5 Time-course monitoring of endometriosis in cynomolgus monkeys by MRI. **(A)** Representative MRI result during time-course monitoring (animal 89102). The right ovarian cyst (in green) can be clearly distinguished from the cysts on the left and in the center (in red). **(B)** Laparoscopic image of the same animal as in A (89102), in which the extent of the cyst could not be observed because it was blocked by a severe adhesion. **(C)** Time courses of total lesion volume. co, colon.

propose that aberrances in abdominal palpation, fecal observations and high levels of serum CA125 are sufficient parameters for this purpose. Gastrointestinal symptoms, such as diarrhea and constipation, were reported to be a major clinical predictive marker of patients with endometriosis (Maroun et al., 2009). If a researcher wants to diagnose endometriosis exactly, we recommend screening for aberrances by palpation first. However, if a researcher needs to prepare a large sample size, it may be more efficient to select animals that produce no feces or are positive for all three parameters as candidates for laparoscopic diagnosis. Moreover, animals in which the first diagnostic examination fails to detect an endometriotic lesion can be pooled with animals that are positive for a single parameter in the screening phase and kept under intensive monitoring, which may further increase the detection rate.

In the course of searching for screening parameters, our report showed for the first time that serum CA125 levels correlated with the presence of chocolate cysts in monkeys with endometriosis, and this finding is consistent with a report in humans (Muyldermans et al., 1995). So far, reports of CA125 in monkeys have been limited and inconclusive—in rhesus monkeys, CA125 levels were found to correlate with the severity of endometriosis (Rippy et al., 1996), but were found to have no correlation in baboons (Falconer et al., 2005)—and there are no previous reports of CA125 levels in cynomolgus monkeys with endometriosis. Our findings suggest that serum CA125 is a useful marker to identify monkeys with chocolate cysts, although it seems not to be helpful to identify monkeys with only peritoneal endometriosis without endometrioma. Despite their paradoxical nature, our findings provide evidence to support the view that endometriosis in cynomolgus monkeys is similar to that in humans.

Table II Comparison of characteristics of laparoscopy and magnetic resonance imaging.

Item	Laparoscopy	MRI
Diagnosis	Easily possible	Possible, especially for large lesions
Quantification of lesion size	Semi-quantification for any lesion	Possible for large cystic lesions
Qualification of the lesion	Location, color, depth, and extension of even small lesions and adhesions were evaluable	Location of large lesions was evaluable (even if the lesion was hidden behind an adhesion)
Staging	Possible with r-AFS score	Not possible
Invasiveness of the procedure	Relatively invasive	Non-invasive
Technical expertise	Higher skill is required	Skills for MRI operation are required

r-AFS, revised American Fertility Society.

It was reported that the prevalence of endometriosis in cynomolgus monkeys autopsied at this colony was 28.7% (Ami et al., 1993); however this study does not give clear data on the incidence of spontaneous endometriosis in living cynomolgus monkeys because we conducted a diagnosis in only 29 monkeys, and not in the general population. Retrospective analysis of the 15 diagnosed monkeys in our study showed that one monkey was 6–10 years old, nine monkeys were 11–15 years old, and five monkeys were 16–20 years old. No monkeys aged 21–25 years proceeded to the diagnostic phase. These findings suggest that the screening system would be more efficient if a colony for an endometriosis model is maintained in the 11–20-year-old age group, which has a greater frequency of menstrual bleeding and active ovarian function. In drug development, the spontaneous endometriosis model presents an opportunity to analyze the etiology of disease progress and can be used to explore the mechanism of a new drug because they have not only peritoneal endometriosis but also endometrioma with chronic fibrotic lesion and immune cells that are similar to women with endometriosis. On the other hand, the low detection rate is a disadvantage in studies that require a large number of animals. It is possible to increase the number of study subjects easily by supplementing this model with an induced model, as is done in baboon studies (Donnez et al., 2013; Harirchian et al., 2012), though the characteristics of the induced model have yet to be analyzed thoroughly.

Our laparoscopic findings showed that spontaneous endometriosis in cynomolgus monkeys had various disease manifestations in terms of the location, size and color of lesions, as well as the location and extension of adhesions. As these manifestations were similar to those of clinical cases, and since disease staging would be essential in a drug efficacy model, we tried to optimize the clinical r-AFS score for endometriosis in cynomolgus monkeys. To modify the r-AFS score, first we changed the criteria for lesion size (to 5 and 15 mm) because cynomolgus monkeys are smaller than humans. The other modification was to add the item of adhesion at the vesicouterine pouch (complete, partial, open), similar to that for the pouch of Douglas, because adhesions at this pouch were observed more frequently in cynomolgus monkeys (44.4%; 4/9) than in humans (see below). With those minor

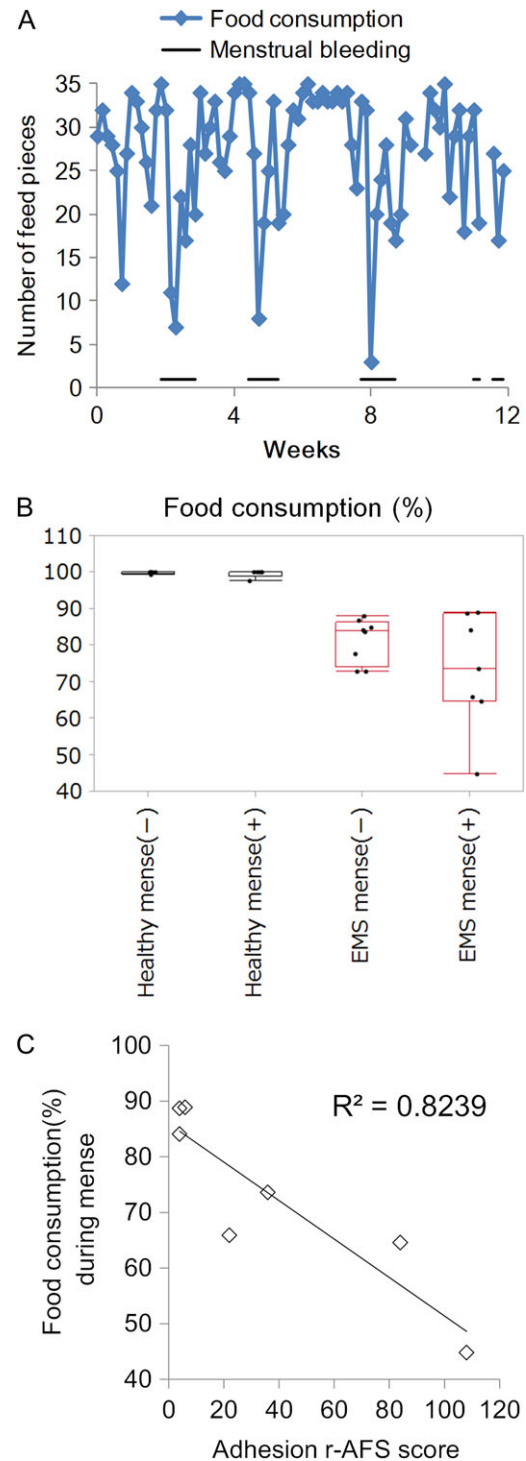


Figure 6 Food consumption and its relationship with the menstrual cycle and adhesion r-AFS score in cynomolgus monkeys. **(A)** Representative data of time-course changes in food consumption and menstrual bleeding (animal 93124). **(B)** Mean of food consumption (%) in periods with or without menses in healthy monkeys and monkeys with endometriosis. Bars in the box-and-whisker plots from the top: maximum, upper quartile, median, lower quartile, and minimum. Dot: mean of individual data for each animal. **(C)** Correlation of food consumption during menses (%) and adhesion r-AFS score ($N = 7$).

Table III Characteristics of endometriosis models in baboons and cynomolgus monkeys.

Item	Baboon	Cynomolgus monkey
Screening		
Serum CA125	Not applicable (serum CA125 was not elevated despite endometriosis) (Falconer et al., 2005)	Applicable
Palpation	May be applicable (one report of diagnosis with palpation) (DaRif et al., 1984).	Applicable
General condition	No report of monitoring general conditions (feces, food consumption, etc.) in baboons with endometriosis Menstruation was detectable from menstrual flow and perineal skin monitoring (D'Hooghe et al., 2009)	Applicable (laboratory setting is sufficient and individual monitoring of feces and food consumption is applicable) Menstruation was detectable from menstrual bleeding
Diagnosis with staging		
Laparoscopic observation	Applicable (D'Hooghe et al., 1992)	Applicable
Staging	Applicable with modified r-AFS score (D'Hooghe et al., 1996b)	Applicable with modified r-AFS score
Monitoring		
Laparoscopic observation	Applicable (D'Hooghe et al., 1996a; 1996b)	Applicable
Lesion size and location by MRI	No report	Applicable
Pharmacological endpoint		
Endometriosis-associated biological parameter	No report	Food consumption
Gene expression profiling	Limited to reported genes or need to be sequenced (whole genome sequence is not reported)	Commercial microarray is available and primers can be designed from sequence database (open access) Higashino et al. (2012)
Analysis of protein expression	Need to check cross-reactivity	ELISA and Luminex kits are commercially available

modifications, it was possible to calculate the r-AFS score and assign disease stages for each animal.

Monitoring by laparoscopy showed that disease status was stable and sometimes progressed for several months (up to 7 months). We also assessed MRI as a procedure for monitoring spontaneous endometriosis in cynomolgus monkeys, since it has received much attention recently as a non-invasive method in the clinical setting (Bazot et al., 2004; Takahashi et al., 2016), and compared their individual merits and demerits (Table II). In this trial, we found that MRI can detect large cystic lesions and give information on cyst volume and can sometimes detect a lesion that laparoscopic monitoring had missed because the view was obstructed.

From the detailed monitoring used in this study, we noticed for the first time that food consumption in monkeys with spontaneous endometriosis decreased during menstruation and was correlated with the adhesion r-AFS score. We considered that food consumption during the menstrual phase can serve as an endpoint for an endometriosis-associated biological parameter in a cynomolgus endometriosis model. Knowing that human endometriosis patients have severe menstrual pelvic pain and reduced quality of life (Aubry et al., 2017), we speculated that this 'biological response' in cynomolgus monkeys may be caused by pain and reduced quality of life. Since the solid food we used is commercially available, and individual monitoring of food consumption is the usual practice in many research laboratories, data from other facilities will also be important to increase the validity of our finding.

After reviewing all the characteristics discussed above, we compared spontaneous endometriosis in baboons and cynomolgus

monkeys as experimental models (Table III). The strength of using baboons as an endometriosis model is that they are easy to observe because female baboons weigh 8–15 kg (D'Hooghe et al., 2009), while cynomolgus monkeys weigh 2–5 kg. As a model for pharmacological evaluation, the strengths of using cynomolgus monkeys are that handling the animals and analyzing their general conditions are relatively easy. In addition, many parameters are available as part of normal laboratory practice, including mRNA and protein expression, and importantly, for genetic analysis of this model, the whole genome of cynomolgus monkeys has been fully sequenced (Higashino et al., 2012). Analyzing mRNA and protein expression and examining the whole genome sequence in endometriosis of cynomolgus monkeys are efficient methods for clarifying its pathogenesis and developing a novel drug. In addition, since we found for the first time in NHPs that changes in food consumption during the menstrual phase can be set as an endometriosis-associated biological parameter, it may be worth verifying the relationship between the menstrual cycle, endometriosis status, and food consumption in baboons.

In conclusion, spontaneous endometriosis in cynomolgus monkeys satisfied the three requirements for an endometriosis animal model: screening was available using CA125, palpation and observation of feces; disease status could be evaluated, even with small lesions, and staging based on r-AFS score modified for cynomolgus monkeys was applicable; and monitoring the time course of disease status using laparoscopy and MRI was established. In the monitoring phase, we found that disease status was stable, and several aspects of disease manifestation were gross, with histological findings similar to those in

human clinical cases. In addition, we found that food consumption may be useful as an endometriosis-associated biological parameter. On the basis of these data, we considered that spontaneous endometriosis in cynomolgus monkeys is a useful model to evaluate disease progression and drug efficacy.

Supplementary data

Supplementary data are available at *Human Reproduction* online.

Authors' roles

A.N.-K.: designed, performed and supervised the experiments, analyzed and interpreted the data, and wrote the article. S.N., S.O., K.T. and H.T.: acquired the data and prepared the figures. A.K. and M.S.: analyzed and interpreted the data, and engaged in critical discussions. T.S. and R.K.: designed, performed and supervised the experiments, analyzed and interpreted the data, engaged in critical discussions. All authors approved the article and its submission.

Funding

No external funds were used for this study.

Conflict of interest

A.N.-K., K.T., H.T., A.K. and M.S. are full-time employees of Chugai Pharmaceutical Co., Ltd. RK received a consultancy fee from Chugai Pharmaceutical Co., Ltd., and lecture fees from Chugai Pharmaceuticals, Japan Vaccine Co. Ltd., MSD, Mochida Co. Ltd., Roche Diagnostics, and BD, unrelated to the submitted work. S.N., S.O. and T.S. have nothing to declare.

References

- Ami Y, Suzaki Y, Goto N. Endometriosis in cynomolgus monkeys retired from breeding. *J Vet Med Sci* 1993;**55**:7–11.
- Andrews WC, Buttram Jr VC, Behrman SJ, Carmichael E, Cohen M, Dmowski P, Eward R, Guzick D, Jones HW Jr, Kistner R *et al*. Revised American Fertility Society classification of endometriosis: 1985. *Fertil Steril* 1985;**43**:351–352.
- Aubry G, Panel P, Thiollier G, Huchon C, Fauconnier A. Measuring health-related quality of life in women with endometriosis: comparing the clinical properties of the Endometriosis Health Profile-5 (EHP-5) and the EuroQol-5D (EQ-5D). *Hum Reprod* 2017;**32**:1258–1269.
- Bazot M, Darai E, Hourani R, Thomassin I, Cortez A, Uzan S, Buy JN. Deep pelvic endometriosis: MR imaging for diagnosis and prediction of extension of disease. *Radiology* 2004;**232**:379–389.
- Braundmeier AG, Fazleabas AT. The non-human primate model of endometriosis: research and implications for fecundity. *Mol Hum Reprod* 2009;**15**:577–586.
- DaRif CA, Parker RF, Schoeb TR. Endometriosis with bacterial peritonitis in a baboon. *Lab Anim Sci* 1984;**34**:491–493.
- Donnez O, Van Langendonck A, Defrere S, Colette S, Van Kerk O, Dehoux JP, Squifflet J, Donnez J. Induction of endometriotic nodules in an experimental baboon model mimicking human deep nodular lesions. *Fertil Steril* 2013;**99**:783–789.e783.
- Dunselman GA, Vermeulen N, Becker C, Calhaz-Jorge C, D'Hooghe T, De Bie B, Heikinheimo O, Horne AW, Kiesel L, Nap A *et al*. ESHRE guideline: management of women with endometriosis. *Hum Reprod* 2014;**29**:400–412.
- D'Hooghe TM, Bambra CS, Cornillie FJ, Isahakia M, Koninckx PR. Prevalence and laparoscopic appearance of spontaneous endometriosis in the baboon (*Papio anubis*, *Papio cynocephalus*). *Biol Reprod* 1991;**45**:411–416.
- D'Hooghe TM, Bambra CS, De Jonge I, Lauweryns JM, Koninckx PR. The prevalence of spontaneous endometriosis in the baboon (*Papio anubis*, *Papio cynocephalus*) increases with the duration of captivity. *Acta Obstet Gynecol Scand* 1996a;**75**:98–101.
- D'Hooghe TM, Bambra CS, Isahakia M, Koninckx PR. Evolution of spontaneous endometriosis in the baboon (*Papio anubis*, *Papio cynocephalus*) over a 12-month period. *Fertil Steril* 1992;**58**:409–412.
- D'Hooghe TM, Bambra CS, Raeymaekers BM, Koninckx PR. Serial laparoscopies over 30 months show that endometriosis in captive baboons (*Papio anubis*, *Papio cynocephalus*) is a progressive disease. *Fertil Steril* 1996b;**65**:645–649.
- D'Hooghe TM, Kyama CM, Chai D, Fassbender A, Vodolazkaia A, Bokor A, Mwenda JM. Nonhuman primate models for translational research in endometriosis. *Reprod Sci* 2009;**16**:152–161.
- Falconer H, Bambra CS, Chai D, Cornillie FJ, Hill JA, D'Hooghe TM. The effect of endometriosis, cycle stage, lymphocyte suppression and pregnancy on CA-125 levels in peritoneal fluid and serum in baboons. *Hum Reprod* 2005;**20**:3033–3038.
- Fanton JW, Hubbard GB. Spontaneous endometriosis in a cynomolgus monkey (*Macaca fascicularis*). *Lab Anim Sci* 1983;**33**:597–599.
- Greene R, Stratton P, Cleary SD, Ballweg ML, Sinai N. Diagnostic experience among 4,334 women reporting surgically diagnosed endometriosis. *Fertil Steril* 2009;**91**:32–39.
- Harirchian P, Gashaw I, Lipskind ST, Braundmeier AG, Hastings JM, Olson MR, Fazleabas AT. Lesion kinetics in a non-human primate model of endometriosis. *Hum Reprod* 2012;**27**:2341–2351.
- Higashino A, Sakate R, Kameoka Y, Takahashi I, Hirata M, Tanuma R, Masui T, Yasutomi Y, Osada N. Whole-genome sequencing and analysis of the Malaysian cynomolgus macaque (*Macaca fascicularis*) genome. *Genome Biol* 2012;**13**:R58.
- Maroun P, Cooper MJ, Reid GD, Keirse MJ. Relevance of gastrointestinal symptoms in endometriosis. *Aust N Z J Obstet Gynaecol* 2009;**49**:411–414.
- Merrill JA. Spontaneous endometriosis in the Kenya baboon (*Papio doguera*). *Am J Obstet Gynecol* 1968;**101**:569–570.
- Muyldermans M, Cornillie FJ, Koninckx PR. CA125 and endometriosis. *Hum Reprod Updat* 1995;**1**:173–187.
- Nishimoto-Kakiuchi A, Netsu S, Matsuo S, Hayashi S, Ito T, Okabayashi S, Yasmin L, Yuzawa K, Kondoh O, Kato A *et al*. Characteristics of histologically confirmed endometriosis in cynomolgus monkeys. *Hum Reprod* 2016;**31**:2352–2359.
- Rippy MK, Lee DR, Pearson SL, Bernal JC, Kuehl TJ. Identification of rhesus macaques with spontaneous endometriosis. *J Med Primatol* 1996;**25**:346–355.
- Story L, Kennedy S. Animal studies in endometriosis: a review. *ILAR J* 2004;**45**:132–138.
- Takahashi N, Yoshino O, Maeda E, Naganawa S, Harada M, Koga K, Hiraie O, Nakamura M, Tabuchi T, Hori M *et al*. Usefulness of T2 star-weighted imaging in ovarian cysts and tumors. *J Obstetrics Gynaecol Res* 2016;**42**:1336–1342.
- Yamanaka A, Kimura F, Takebayashi A, Kita N, Takahashi K, Murakami T. Primate model research for endometriosis. *Tohoku J Exp Med* 2012;**226**:95–99.