

## Special Report

For reprint orders, please contact: [reprints@futuremedicine.com](mailto:reprints@futuremedicine.com)

## Endometriosis and ovarian reserve

Endometriosis is characterized by development of the endometrial tissue outside the uterus like ovary, pelvic peritoneum, pelvic organs, and affects 6–10% of reproductive-aged women. The prevalence of endometrioma is 17–44% of women with endometriosis [1–4]. Since endometriosis is mainly a disease for the women at their reproductive ages, it is important to consider ovarian reserve when managing the cases with ovarian endometriosis. There has been a long debate whether the endometrioma *per se* decreases the ovarian reserve and/or surgery for endometrioma – either by laparoscopy or by laparotomy – decreases it. Although the dispute for these questions is not totally settled down, in this article, we would like to give some clues for the answers in view of the literature.

### The pathophysiology of endometrioma

Two main pathophysiologic theories have been described for the development of endometrioma. According to the first theory proposed by Hughesdon, ovarian endometrioma is being developed by accumulation of menstrual debris from active endometrial implants that is located into ovary from cortex invagination [5]. Second theory, proposed by Nisolle and Donnez, states that endometriomas occur from the coelomic metaplasia of the invaginated ovarian cortical tissue [6]. Both theories were verified 90–100% of cases with endometriomas [7,8].

### Presence of ovarian endometriosis on ovarian reserve

There have been some studies on the impact of the ovarian endometriosis itself on the ovarian tissue. It has been reported that the ovarian tissue adjacent to the endometrioma wall is morphologically altered and possibly not functional [9]. Kitajima *et al.* reported that follicular density surrounding the endometrioma wall was significantly lower compared with the contralateral normal ovarian cortical tissue [10]. In another study, the rate of the follicles in healthy

ovarian tissue adjacent to the endometrioma wall was lower than other ovarian cyst in patients aged <35 years, though, to some extent the difference in the preoperative GnRHa medication between the groups (85.2% in the endometrioma group, 4.2% in the control group) might explain the evaluation process [11]. In epitome, based on histological studies, a detrimental effect on the ovarian follicular structure may already be present before surgery in women with endometrioma. However, there are some contradictory findings, too. In a retrospective analysis, number of antral follicles and retrieved oocytes in women with unilateral endometrioma did not differ [12]. In another similar study, in women with unilateral endometrioma, response to ovarian hyperstimulation did not differ between the normal ovary and the ovary-contained endometrioma [13].

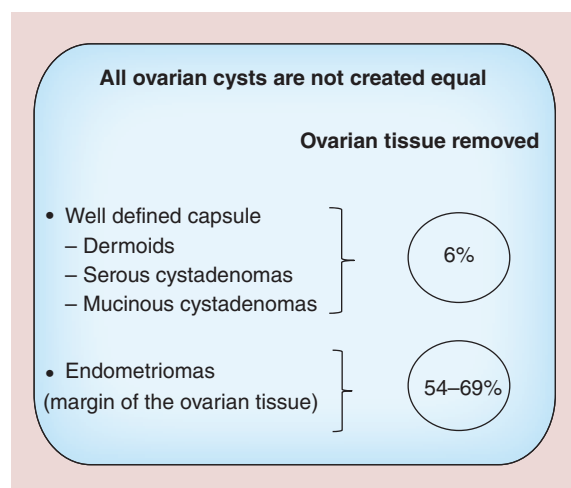
There are several reports on the impact of endometrioma on ovarian reserve. Shebl *et al.* reported that serum AMH level was significantly lower in patients with endometriosis (n = 153) than in controls (n = 306). In the subgroup analysis, a significant difference on the serum AMH level was only found in women with severe endometriosis

Engin Oral\*, Berfu Demir & Umit Inceboz

\*Author for correspondence:  
[eoral@superonline.com](mailto:eoral@superonline.com)

(rAFS III–IV) in comparison with the controls. Nevertheless, evaluations in the severe endometriosis group were not documented as either endometrioma or deep infiltrating endometriosis in this study [14]. In a retrospective study, Hwu *et al.* reported that serum AMH level was significantly lower in the endometrioma group (n = 141) than in the controls (n = 1323). However, in this study, excluding the endometrioma in controls was performed by using ultrasound only, surgical verification was not performed [15]. Recently, Uncu *et al.* presented a prospective study comparing 30 women with endometrioma and 30 healthy controls. Serum AMH level and AFC were significantly lower in patients with endometrioma compared with the controls. Again, in this study, the absence of endometriosis in the control group was not investigated surgically [16]. Streuli *et al.* evaluated 313 women who had histologically diagnosed endometriosis. Forty percent of the women were infertile; 254 of them had not prior endometriosis surgery. Serum AMH levels were comparable in the control groups compared with women with current endometriosis without prior surgery. In the endometriosis group with no previous surgery, serum AMH levels were similar irrespective of the severity of endometriosis (superficial peritoneal lesion, deep infiltrating endometriosis and endometrioma). Thus, the authors concluded that endometriomas *per se* did not decrease the ovarian reserve; instead, the surgery performed for endometrioma resulted in diminished ovarian reserve revealed by decreased AMH levels [17].

After all, the harmful effect of ovarian endometrioma on the ovarian reserve *per se* is possible but not certain.



**Figure 1. The structural differences among different ovarian cysts yield different amounts of adjacent ovarian tissue when they are removed.**  
Data taken from [9].

### Conservative surgical management of endometriosis

Treatment options of the endometriosis are medical and surgical. Available medical treatment options are based on the blockage of the ovarian function. Therefore, these agents are only useable for the treatment of pain related symptoms. Conservative surgical management of the endometriosis for infertility includes ablation and/or resection of the endometriotic implants, reconstruction of the tuba–ovarian relationship and endometrioma surgery. Excisional surgery, drainage and ablation have been established conservative surgical treatment options for endometrioma. High recurrence rate versus potential harmful effects on the ovarian reserve make it difficult to select the most effective treatment modality for endometriomas.

### Endometrioma surgery & ovarian reserve

*Primum non nocere!* (First, don't do harm!)

It has been shown that ovarian endometrioma was structurally different from the other types of ovarian cysts [9]. Figure 1 shows the difference in the amount of ovarian healthy tissue removed by the removal of the different ovarian cysts. Considering the postulated pathogenesis, the wall of endometrioma is pseudocapsule; hence, different amounts of healthy ovarian tissue are removed during the stripping of the endometrioma. Consistent evidence revealed that surgery-mediated damage on the ovarian reserve is observed with the excision of the endometrioma using stripping technique. Moreover, vascular injury due to electrosurgical coagulation [18] and inflammatory reaction following the surgery are other reasons for the ovarian damage [19,20].

Recently, the impact of the surgical excision of endometrioma on ovarian reserve was evaluated by two systematic reviews. Eight prospective studies including 237 patients were analyzed in the meta-analysis reported by Raffi *et al.* Studies were published between 2009 and 2011. Ovarian reserve was determined by serum AMH level in all studies. Preoperative serum AMH level was 3.0 ng/ml, and significantly decreased (38%) following the surgery. A reduction of 30% in serum AMH level was observed in patients undergoing unilateral endometrioma cystectomy, while 44% reduction was following the bilateral endometrioma surgery. AFC were evaluated in three studies including 79 patients. There was no significant change in AFC [21]. Eleven studies were included in the review reported by Somigliana *et al.* [22]. Nine of 11 studies documented significant reduction in the serum AMH level following the surgery. Risk factors associated with reduction of serum AMH levels were evaluated with the multivariate analysis including three of the 11 studies. Bilaterality of

the endometrioma, preoperative serum AMH level and presence of the healthy ovarian tissue adjacent to the cyst wall are accepted as the independent risk factors for the AMH decline [10,23–24]. Uncu *et al.* reported that serum AMH levels are decreased by 7% in patients with unilateral endometrioma and 14.6% in patients with bilateral endometrioma on 6 months control following the surgery. In the subgroup analysis, a significant decrement in serum AMH level was observed following the excision of bilateral endometrioma. However, the rate of decline on the serum AMH level was not significantly correlated with the laterality of the endometriomas [16]. In another recent study, unilateral removal of endometrioma induces a decrease in both AMH levels and AFC which sustained even 6 months later [25]. In a study by Benaglia *et al.* [13], 93 women had undergone surgery for unilateral endometrioma; these patients had ovarian stimulation for IVF. Among 93 patients, 12 had absent follicular growth on the operated side whereas contralateral ovary showed follicular growth. Thus, ESHRE guidelines recommend the clinicians to counsel the women with endometrioma regarding the risk of diminished ovarian reserve after ovarian surgery (Figure 2) [26].

In the prospective randomized trial, Var *et al.* compared the impact of the excision versus coagulation on ovarian volume and AFC, on either side of patients with bilateral endometrioma (n = 48). 6 months after the surgery, AFC and ovarian volume were significantly lower following the excision technique compared with the coagulation [27].

Two-step or three-step and combined technique are available surgical approaches to decrease the harmful effects of the stripping technique. Two-step procedure or three step procedure (if given GnRH analogs were accepted as a procedure) is described as follows: drainage, irrigation and biopsy are performed on the first

The GDG recommends that clinicians counsel women with endometrioma regarding the risks of reduced ovarian function after surgery and the possible loss of the ovary. The decision to proceed with surgery should be considered carefully if the woman has had previous ovarian surgery.

GPP

**Figure 2. The recommendation on the counseling the patient about the possible risk of reduced ovarian reserve after ovarian surgery for endometrioma.**

Information taken from ESHRE Guidelines-2013; no permission needed.

procedure; GnRH analog is given during the 3 months; cyst wall is vaporized on the second operation. Combined technique is included partially cystectomy and CO<sub>2</sub> laser vaporization of the remained cyst wall especially close to ovarian hilus [28]. In the prospective randomized trial, Tsolakidis *et al.* compared the impact of cystectomy versus three-step procedure on the ovarian reserve in patients with endometrioma. On the sixth-month control, serum AMH level significantly declined following cystectomy group (n = 10) but did not change following the three-step procedure (n = 10). At the 6th month control, AFC was significantly higher in patients following the three-step procedure, but similar after the cystectomy procedure [29]. Donnez *et al.* reported that combined technique for the new conservative surgical management of endometrioma did not reveal deleterious effect on the ovarian reserve evaluated with the AFC and ovarian volume [30].

There is also an interesting finding regarding to ovarian reserve after ovarian surgery and recurrence rate. In a retrospective analysis of cases with recurrent

### Executive summary

- Endometriomas affect the ovarian reserve either by themselves or by the surgery performed for the management.
- A detrimental effect on the ovarian follicular structure may already be present before surgery in women with endometrioma.
- Surgery-mediated damage on the ovarian reserve is observed with the excision of the endometrioma using stripping technique. Vascular injury and inflammatory reaction following the surgery are other reasons for the ovarian damage.
- Two-step or three-step and combined technique are available surgical approaches to decrease the harmful effects of the stripping technique.
- An evaluation of the ovarian reserve is recommended in women with endometrioma by means of the anti-Müllerian hormone, and the ultrasonographic antral follicle count. Evaluation of ovarian reserve by AMH levels and AFC immediately before and 3 months after surgery is recommended, and this respected information is helpful for the planning of further treatment.
- During to surgery for endometrioma, identification of the cleavage and avoidance of blind coagulation – especially close to the hilus – should be remembered.

endometrioma after unilateral ovarian surgery, it has been shown that recurrence rate was higher when the ovarian reserve was better [31].

#### Financial & competing interests disclosure

The authors have no relevant affiliations or financial involvement with any organization or entity with a financial

interest in or financial conflict with the subject matter or materials discussed in the manuscript. This includes employment, consultancies, honoraria, stock ownership or options, expert testimony, grants or patents received or pending, or royalties.

No writing assistance was utilized in the production of this manuscript.

#### References

- Bulun SE. Endometriosis. *N. Engl. J. Med.* 360(3), 268–279 (2009).
- Matzuk MM. Gynecologic diseases get their genes. *Nat. Med.* 11(1), 24–26 (2005).
- Busacca M, Vignali M. Ovarian endometriosis: from pathogenesis to surgical treatment. *Curr. Opin. Obstet. Gynecol.* 15(4), 321–326 (2003).
- Redwine DB. Ovarian endometriosis: a marker for more extensive pelvic and intestinal disease. *Fertil. Steril.* 72(2), 310–5 (1999).
- Hughesdon PE. The structure of endometrial cysts of the ovary. *J. Obstet. Gynaecol. Br. Emp.* 64(4), 481–487 (1957).
- Donnez J, Nisolle M, Gillet N, Smets M, Bassil S, Casanas-Roux F. Large ovarian endometriomas. *Hum. Reprod.* 11(3), 641–646 (1996).
- Nisolle M, Donnez J. Peritoneal endometriosis, ovarian endometriosis, and adenomyotic nodules of the rectovaginal septum are three different entities. *Fertil. Steril.* 68(4), 585–596 (1997).
- Brosens IA, Puttemans PJ, Deprest J. The endoscopic localization of endometrial implants in the ovarian chocolate cyst. *Fertil. Steril.* 61(6), 1034–1038 (1994).
- Muzii L, Bianchi A, Croce C, Mancini N, Panici PB. Laparoscopic excision of ovarian cysts: is the stripping technique a tissue-sparing procedure? *Fertil. Steril.* 77(3), 609–614 (2002).
- Kitajima M, Defrere S, Dolmans MM *et al.* Endometriomas as a possible cause of reduced ovarian reserve in women with endometriosis. *Fertil. Steril.* 96(3), 685–691 (2011).
- Kuroda M, Kuroda K, Arakawa A *et al.* Histological assessment of impact of ovarian endometrioma and laparoscopic cystectomy on ovarian reserve. *J. Obstet. Gynaecol. Res.* 38(9), 1187–1193 (2012).
- Almog B, Shehata F, Sheizaf B, Tan SL, Tulandi T. Effects of ovarian endometrioma on the number of oocytes retrieved for *in vitro* fertilization. *Fertil. Steril.* 95(2), 525–527 (2011).
- Benaglia L, Somigliana E, Santi G, Scarduelli C, Ragni G, Fedele L. IVF and endometriosis-related symptom progression: insights from a prospective study. *Hum. Reprod.* 26(9), 2368–2372 (2011).
- Shebl O, Ebner T, Sommergruber M, Sir A, Tews G. Anti muellerian hormone serum levels in women with endometriosis: a case–control study. *Gynecol. Endocrinol.* 25(11), 713–716 (2009).
- Hwu YM, Wu FS, Li SH, Sun FJ, Lin MH, Lee RK. The impact of endometrioma and laparoscopic cystectomy on serum anti-Mullerian hormone levels. *Reprod. Biol. Endocrinol.* 9, 80 (2011).
- Uncu G, Kasapoglu I, Ozerkan K, Seyhan A, Oral Yilmaztepe A, Ata B. Prospective assessment of the impact of endometriomas and their removal on ovarian reserve and determinants of the rate of decline in ovarian reserve. *Hum. Reprod.* 28(8), 2140–2145 (2013).
- Streuli I, De Ziegler D, Gayet V *et al.* In women with endometriosis anti-Mullerian hormone levels are decreased only in those with previous endometrioma surgery. *Hum. Reprod.* 27(11), 3294–3303 (2012).
- Garcia-Velasco JA, Somigliana E. Management of endometriomas in women requiring IVF: to touch or not to touch. *Hum. Reprod.* 24(3), 496–501 (2009).
- Hachisuga T, Kawarabayashi T. Histopathological analysis of laparoscopically treated ovarian endometriotic cysts with special reference to loss of follicles. *Hum. Reprod.* 17(2), 432–435 (2002).
- Li CZ, Liu B, Wen ZQ, Sun Q. The impact of electrocoagulation on ovarian reserve after laparoscopic excision of ovarian cysts: a prospective clinical study of 191 patients. *Fertil. Steril.* 92(4), 1428–1435 (2009).
- Raffi F, Metwally M, Amer S. The impact of excision of ovarian endometrioma on ovarian reserve: a systematic review and meta-analysis. *J. Clin. Endocrinol. Metab.* 97(9), 3146–3154 (2012).
- Somigliana E, Berlanda N, Benaglia L, Vigano P, Vercellini P, Fedele L. Surgical excision of endometriomas and ovarian reserve: a systematic review on serum antimullerian hormone level modifications. *Fertil. Steril.* 98(6), 1531–1538 (2012).
- Hirokawa W, Iwase A, Goto M *et al.* The post-operative decline in serum anti-Mullerian hormone correlates with the bilaterality and severity of endometriosis. *Hum. Reprod.* 26(4), 904–910 (2011).
- Celik HG, Dogan E, Okyay E *et al.* Effect of laparoscopic excision of endometriomas on ovarian reserve: serial changes in the serum anti-Mullerian hormone levels. *Fertil. Steril.* 97(6), 1472–1478 (2012).
- Urman B, Alper E, Yakin K *et al.* Removal of unilateral endometriomas is associated with immediate and sustained reduction in ovarian reserve. *Reprod. Biomed. Online* 27(2), 212–216 (2013).
- ESHRE Endometriosis Guideline Development Group, Guideline of the European Society of Human Reproduction and Embryology September 2013. [www.eshre.eu/Guidelines](http://www.eshre.eu/Guidelines)
- Var T, Batioglu S, Tonguc E, Kahyaoglu I. The effect of laparoscopic ovarian cystectomy versus coagulation in

- bilateral endometriomas on ovarian reserve as determined by antral follicle count and ovarian volume: a prospective randomized study. *Fertil. Steril.* 95(7), 2247–2250 (2011).
- 28 Jadoul P, Kitajima M, Donnez O, Squifflet J, Donnez J. Surgical treatment of ovarian endometriomas: state of the art? *Fertil. Steril.* 98(3), 556–563 (2012).
- 29 Tsolakidis D, Pados G, Vavilis D *et al.* The impact on ovarian reserve after laparoscopic ovarian cystectomy versus three-stage management in patients with endometriomas: a prospective randomized study. *Fertil. Steril.* 94(1), 71–77 (2010).
- 30 Donnez J, Lousse JC, Jadoul P, Donnez O, Squifflet J. Laparoscopic management of endometriomas using a combined technique of excisional (cystectomy) and ablative surgery. *Fertil. Steril.* 94(1), 28–32 (2010).
- 31 Somigliana E, Benaglia L, Vercellini P, Paffoni A, Ragni G, Fedele L. Recurrent endometrioma and ovarian reserve: biological connection or surgical paradox? *Am. J. Obstet. Gynecol.* 204(6), 529.e1–5 (2011).